



Clive Peckar

Newsmaker Interview... Clive Peckar

Schlemm's canal: The New Frontier

Searching for the Holy Grail of bleb-independent glaucoma surgery

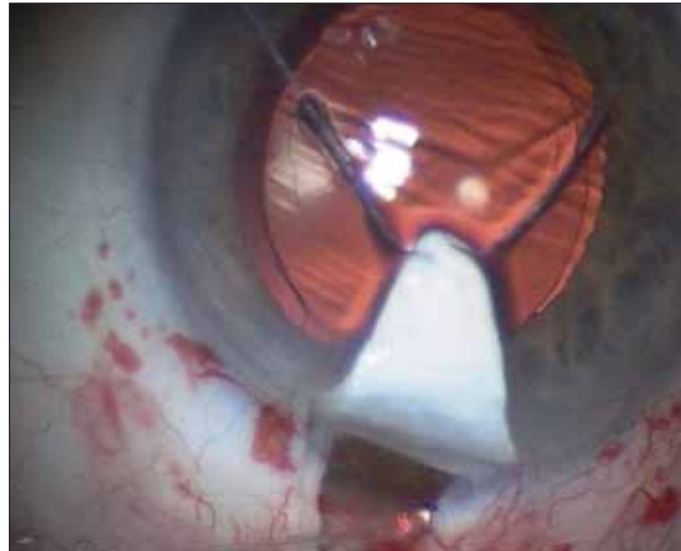
Glaucoma therapy has seen a remarkable evolution in recent years, with a trend away from bleb-dependent filtration surgery and increasing use of pressure-lowering medications. Trabeculectomy, undoubtedly tried and true, comes with its own set of problems. More recently, non-penetrating surgery has moved from the periphery to a more central place in glaucoma management, as the procedures have evolved and the evidence base has grown. *EuroTimes* editor Sean Henahan spoke with Clive Peckar, consultant ophthalmic surgeon, Warrington Hospital, UK, about non-penetrating surgery and its role in the treatment of glaucoma.

ET: Could you first give us some background about non-penetrating glaucoma surgery?

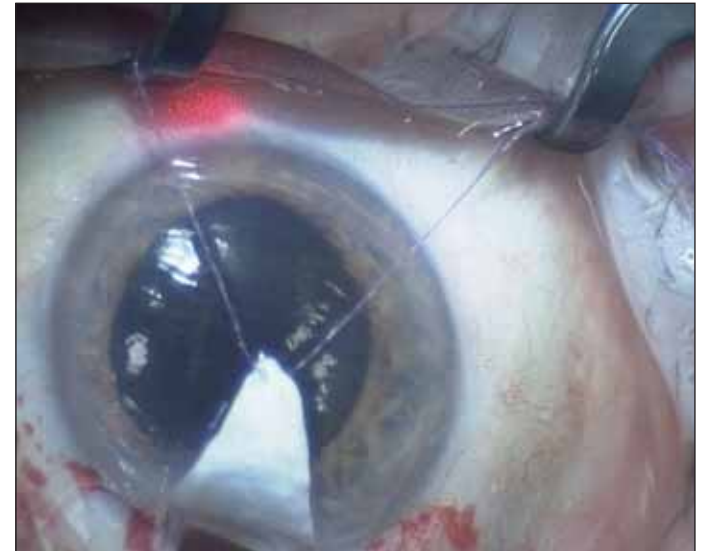
CP: A number of procedures could be called non-penetrating surgery, but penetration isn't the issue. It doesn't so much matter whether you penetrate the anterior chamber or not, what we want to produce is "bleb-independent surgery". Some types of non-penetrating surgery produce a bleb, while viscocanalostomy and canaloplasty are bleb-independent.

"The story begins with Dr Robert Stegmann working in rural South Africa, who found that trabeculectomy had a very high failure rate in Africans. So he was forced to consider alternatives"

The story begins with Prof Robert Stegmann working in rural South Africa, who found that trabeculectomy had a very high failure rate in Africans. So he was forced to consider alternatives. He tried trabeculectomy and visco-trabeculectomy but these also 'scarred-up'. Sixteen years ago he developed viscocanalostomy. I saw his surgery in 1995 and was very impressed. This was a microsurgical procedure attempting to re-establish the physiological drainage of aqueous, via the normal anatomical channels. This was an effort to get past all the problems we know with trabeculectomy, low pressures, choroidal detachments, flat anterior chambers, bleb failures and endophthalmitis.



Microcatheter entering Schlemm's Canal



Catheter at 5.30 o'clock

People were sceptical. They wondered whether this new procedure would work in non-Africans, or whether other surgeons could learn how to do it. Prof Stegmann came to the UK two years later and participated in a course at our institution. It was a turning point. I've been performing viscocanalostomy and more recently canaloplasty as my routine operation ever since.

One of the course participants was Dr Jack Kearney from New York who also took up the challenge.

ET: How is viscocanalostomy performed, and how does it work?

CP: With viscocanalostomy we mark an area on the sclera, usually at 12:00 position, about 5.0mm from the limbus. We make a parabolic opening through the sclera, and produce a superficial sclerectomy flap that is designed to be watertight. Inside that we make a secondary deep sclerectomy flap, cutting down until we can just see the choroid. We cross the scleral spur to Schlemm's canal, de-roof the canal, and create a "Descemet's window". We then remove the deep scleral flap, creating a "scleral lake". Next we dilate the two cut ends of Schlemm's canal (the ostia) with high viscosity sodium hyaluronate, producing a direct access into the Schlemm's canal and the collector channels. We then suture the superficial scleral flap tight, thereby achieving internal bleb-independent surgery. Postoperative care includes topical steroids, anti-prostaglandins, and antibiotics.

ET: What are the advantages of this approach compared with trabeculectomy?

CP: The advantage of this approach is that you produce a deep sclerotomy with a Descemet's window. This prevents gross

hypotony. You have no direct fistula through the sclera, and therefore no flat anterior chambers or choroidal detachments. Therefore, it is suitable for phakics and for bilateral surgery. You have a reduced inflammatory response with reduced synechiae and anterior IOL membranes. You also don't need to do a peripheral iridectomy. The procedure produces internal drainage through Schlemm's canal, so we have no problem with late bleb failure or infection, since there is no bleb.

However, we have since learned that we don't achieve success in all patients. We can't open a collapsed Schlemm's canal, and the collector channels are not open in all patients. Thanks in part to new imaging techniques, pioneered by Robert Stegmann, we have observed that Schlemm's canal closes in some patients, and the collector channels cease to function.

ET: Is this how canaloplasty came about?

CP: Canaloplasty evolved from viscocanalostomy. Dr Jack Kearney from New York had attended our original course in Warrington. After he returned to the US he worked with *iScience* to develop a microcatheter to viscodilate the whole of Schlemm's canal. Prof Stegmann then took this new technique a step further by placing a 360-degree circumferential tension suture within Schlemm's canal to hold the canal and ostia wide open and place the canal under tension.

This came to be known as canaloplasty. The catheter is about 200 microns in diameter, and the soft atraumatic tip is under 250 microns. The tip is illuminated by a helium-neon laser, via a fibre-optic bundle. The catheter also has a delivery lumen for delivery of viscoelastic, as well as a stiffening wire. The catheter is inserted into the ostia, advanced a little, the microscope

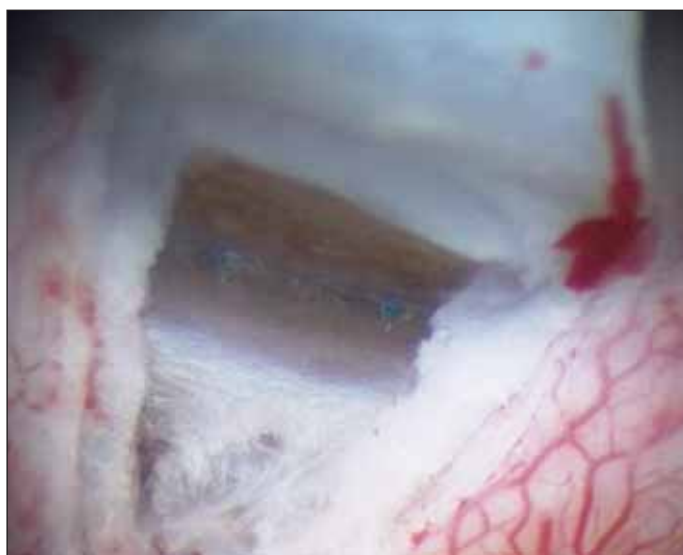
lights are dimmed, and the progress of the catheter can be seen through the canal via the illuminated tip, which shines through the sclera. At every two clock hours 0.5 microlitres of high viscosity sodium hyaluronate are injected to dilate the canal and lubricate the path of the catheter. Once the catheter has passed all the way around the canal, it exits through the opposite ostia. In the majority of cases the catheter will pass unimpeded. Next a 10/0 prolene suture is tied to the end of the catheter, and the catheter is withdrawn in order to place the suture in the canal. The suture is tied under tension on a soft eye, so that when normal tension returns, the suture is at the correct pressure. The suture is locked, and the superficial flap is closed and sutured water-tight. Gonioscopy postoperatively is illustrated.

ET: How long does this surgery take to perform?

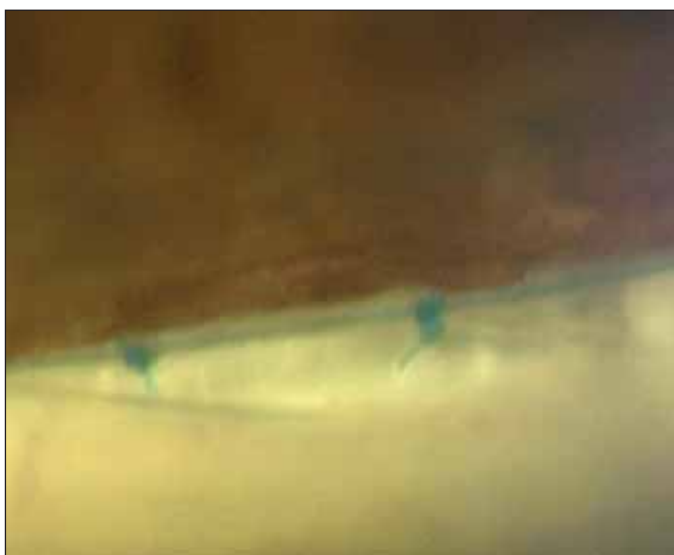
CP: It depends on the speed of the surgeon. I am very slow, so it would take me about one hour to do a canaloplasty. Some surgeons can do the whole surgery within half an hour. It is not a fast operation. It is not as quick as trabeculectomy. If surgeons are not prepared to put the time in when they are learning they shouldn't proceed to this. It is a precise, slow to learn procedure. You have to learn to identify the structures. If you rush you are more likely to traumatise the tissues, which can lead to a poor outcome.

ET: What is the role of ultrasound?

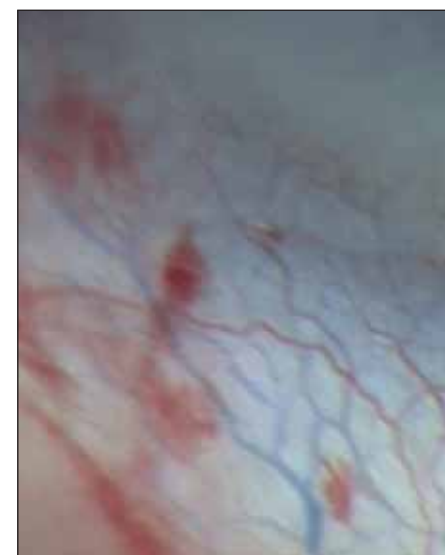
CP: Ultrasound has been very useful in demonstrating the position of the canal and the effects of the surgery on the canal and the tension of the suture in the canal. This is one of a number of things we've just



Suture Knots in Schlemm's canal



Gonio Knots at 2 weeks



CCMA Superior Nasal vessels

Courtesy of Clive Peckar MD

started to get a handle on with this surgery. Prior to these surgeries we weren't really operating on Schlemm's canal at all. I had never seen a Schlemm's canal from the outside prior to doing my first viscocanalostomy.

We are developing other techniques. I've started injecting Trypan blue through the microcatheter, to do microangiography of the collector channels. This allows us to understand which patients will have the best prognosis. The combination of high magnification video, increasingly more sensitive ultrasound, microangiography, and eventually intracanalicular endoscopy will give us the tools we need to understand the structure, function and pathology of Schlemm's canal.

There cannot be one operation for all glaucoma patients. The work that Robert Stegmann has done in South Africa has shown that we are probably dealing with a whole spectrum of change in glaucoma. While the initial change in open-angle glaucoma is a resistance to outflow into Schlemm's canal, as the disease progresses some patients develop closure of Schlemm's canal, and some of these patients will have collector channel closure, caused by herniation of the collapsed canal wall into the collector channel orifices. Only by using these diagnostic tools can we ascertain the changes that are occurring in an individual patient. Eventually this will help us to create some specific strategy for helping patients without the use of fistularising techniques.

ET: How are these procedures doing in clinical studies?

CP: These are still the early days. Speaking broadly about the results, there is an enhanced drop in intraocular tension in canaloplasty patients compared to viscocanalostomy. This is supported by recent report results from US and European ongoing clinical trials. In addition, these studies also suggest there is an added pressure-lowering benefit when the procedures are combined with phacoemulsification cataract surgery in appropriate patients.

In my own patients, 85 per cent of my viscocanalostomy patients achieve IOP of 21 mmHg or less, with 73 per cent achieving 17 mmHg or less. In my canaloplasty patients I have 95 per cent achieving 21 mmHg or less, and 85 per cent at 17 mmHg or lower, with a mean IOP of 15 mmHg. I've only been doing canaloplasty for a relatively short period of time, so we will need some time to gauge the significance of this.

Currently in Europe and the US the indications for this surgery is still "failure of medical treatment". There is anecdotal evidence from Prof Stegmann that earlier surgery might prevent some of these secondary changes such as collector channel closure. We have seen in some of our canaloplasty patients that they achieve a further drop many months after surgery, which we did not see with viscocanalostomy. It may be that holding the canal open, increases drainage through the collector channels. If this is so there may well be advantages to earlier operation. I think it may be a while until we have the evidence to support that.

ET: Sceptics note that viscocanalostomy and canaloplasty are difficult procedures to learn and to perform. Is this going to limit the impact these procedures might have on the demand for glaucoma surgery?

CP: This is a valid question. The difficulty with canaloplasty is the problem of the dissection. With better tools, such as high-definition ultrasound we should end up with a simpler procedure. At the moment we are trying to standardise the procedure so we can better understand exactly how it works. We are proceeding cautiously in order to have good science behind what we are doing. However, because of the very low incidence of complications compared with fistularising surgery, I'm sure the benefits are there. We are only just beginning Schlemm's canal surgery and we are just beginning to get a glimpse of the Holy Grail of bleb-independent surgery. I believe that in the next few years its place in the management of glaucoma will become established.